Normocytic Anemia

Dr. Fatin Al-Sayes, MD, MSc, MRCPath
Consultant Hematology / Assistant Professor
King Abdulaziz University Hospital

Definition:

(MCV 80-100 fL)

Differential diagnosis

(1) hemolysis, haemorrhage

(2) dual deficiency of iron + B12 or folate

(3) anemia of chronic disorders

(4) bone marrow aplasia

(5) bone marrow disease or replacement

(6) hypothyroidism

Aplastic Anemia

Definition:

- Peripheral blood pancytopenia
- Bone marrow failure

- Uncommon
- Peak incidence around 30 years
- Slight male predominance

Etiology:

(1) Idiopathic

(2) Drug induced
- Dose dependant
- Idiosyncratic

(3) Chemical or toxin

(4) Infection
- Hepatitis
- Parvovirus
- TB
- HIV

(5) Pregnancy

(6) Thymoma

(7) Associated with MDS

(8) Paroxysmal nocturnal hemoglobinuria (PNH)

(9) Constitutional
- Fanconi anemia
- Familial aplastic anemia
- Dyskeratosis congenita

Pathophyisology:

(1) Substantial reduction in the number of stem cells

(2) Immune mediated mechanism

(3) Defective hematopoietic microenvironment

Clinical features:

- Bleeding e.g. bruising, bleeding gum
- Weakness. Symptoms of anemia.
- Infection e.g. mouth.

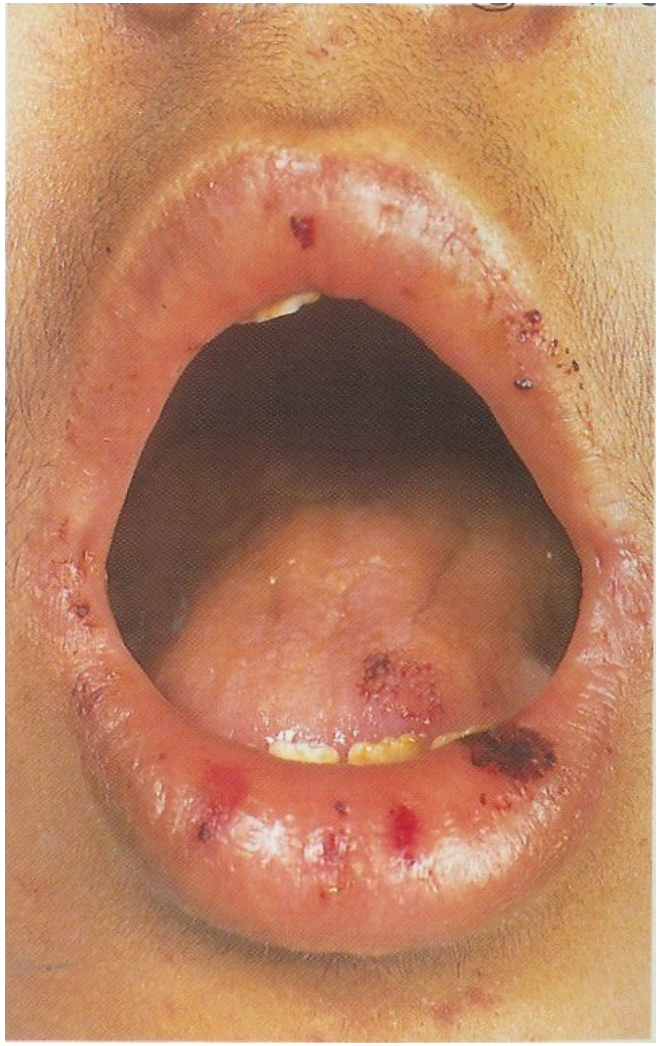

Physical examination:

- Pallor
- Purpura: ecchymosis or petechiae
- Gingivitis, stomatitis, pharyngitis etc
- Absence of lymphadenopathy, hepatomegaly and splenomegaly are common

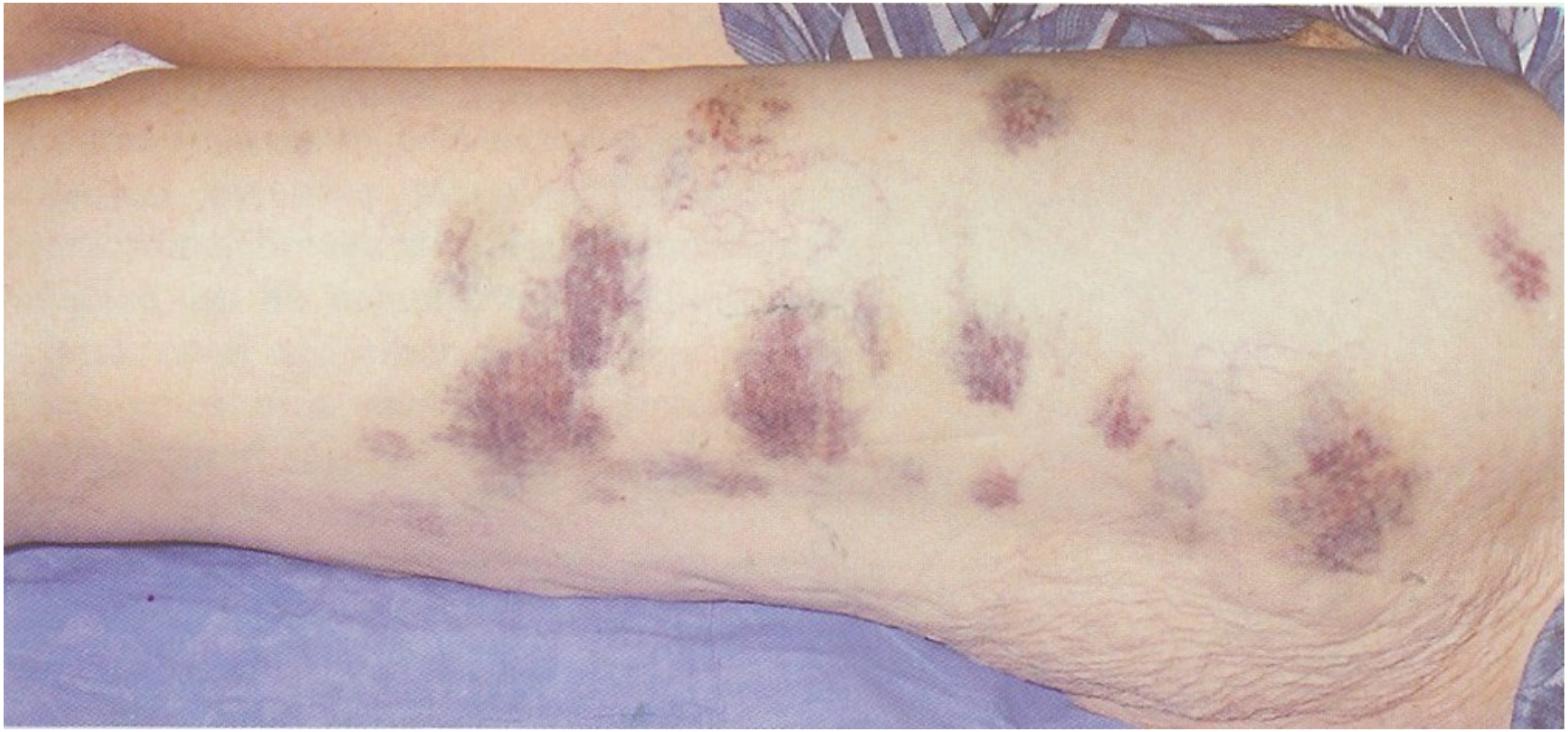

Laboratory features:

CBC:

- Normocytic-normochromic anemia
- ↓↓ reticulocyte count
- Leucopenia
- Thrombocytopenia

Peripheral blood film:

- Pancytopenia
- No abnormal cells

Laboratory features (cont):

Bone marrow aspiration and trephine biopsy:

- Hypocellularity
- ↑↑ fat cells numbers
- Iron stores usually increased

Cytogenetic analysis:

Certain abnormalities may suggest a higher risk of myelodysplasia and acute leukemia

Flow cytometry:

CD_{56}, CD_{59} may be absent, indicating the presence of PNH.

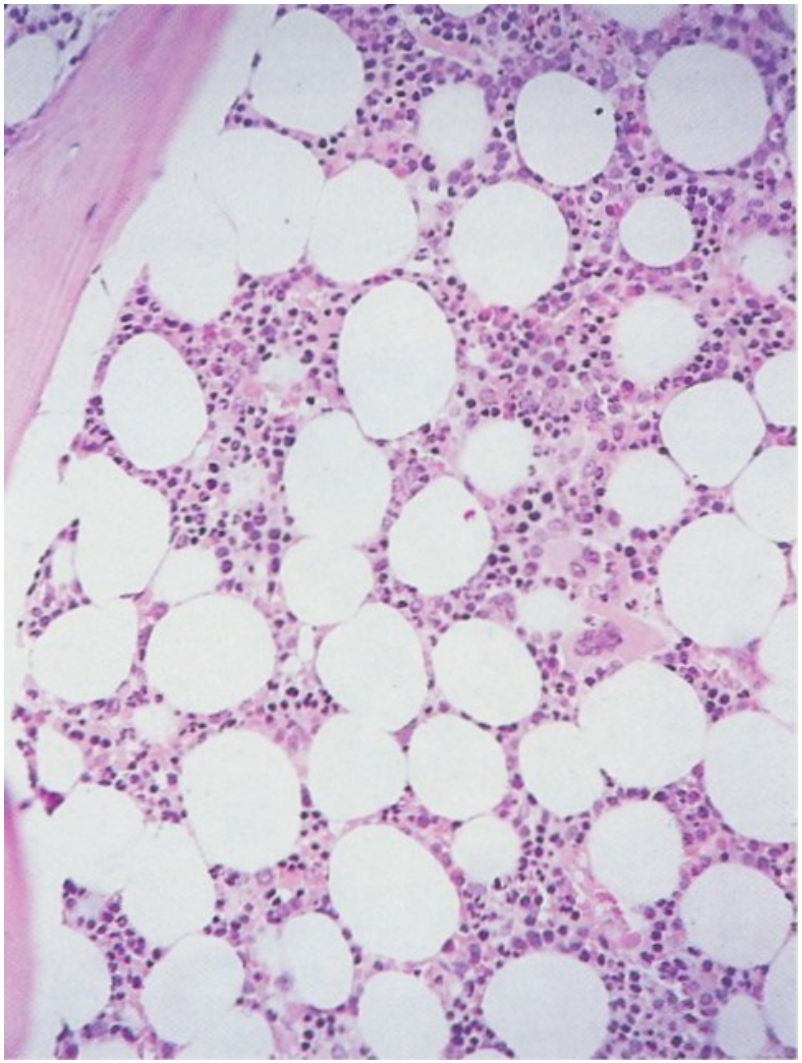

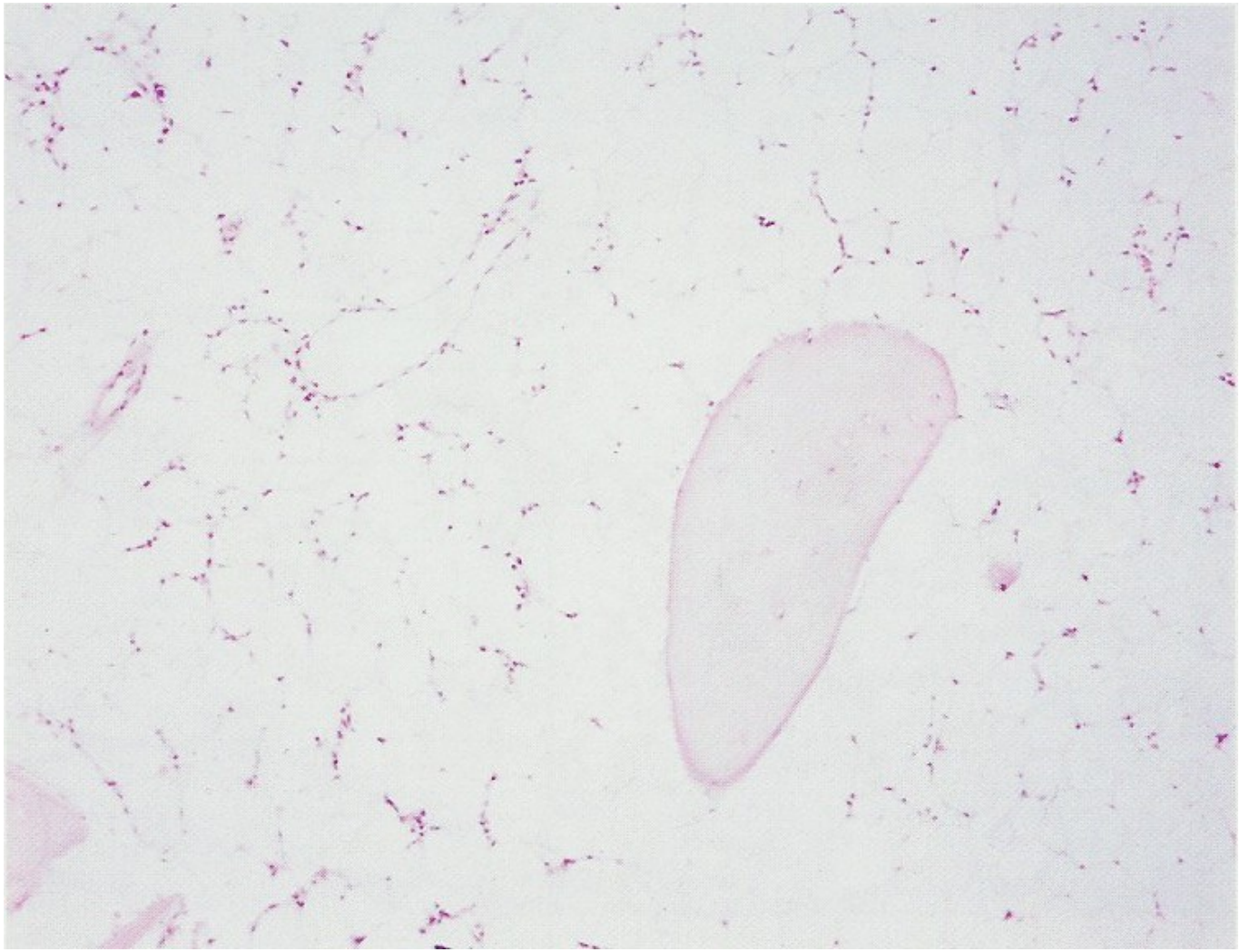

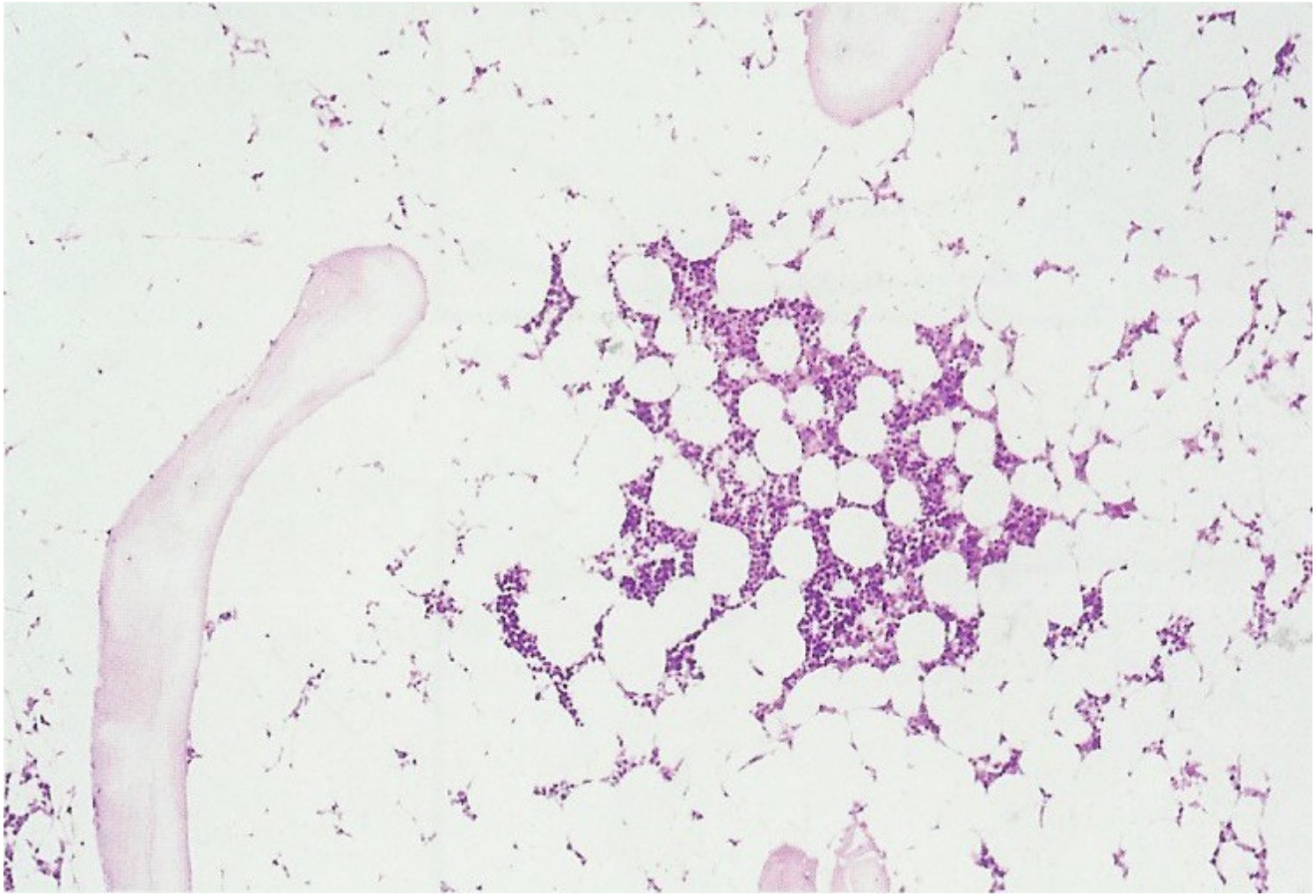

Prognosis:

Median survival is about 12 months.

Differential diagnosis of aplastic anemia:

- Bone marrow infiltration
- Leukemia, MDS, myeloma
- Hypersplenism
- Megaloblastic anemia
- Myelofibrosis
- PNH

Fanconi Anemia

- Congenital
- Recessive inheritance

Clinical features:

- Growth retardation
- Microcephaly, absent radii or thumbs
- Renal tract defect e.g. pelvic

Kidney or horseshoe kidney

- Skin defect e.g. cafe au lait patches

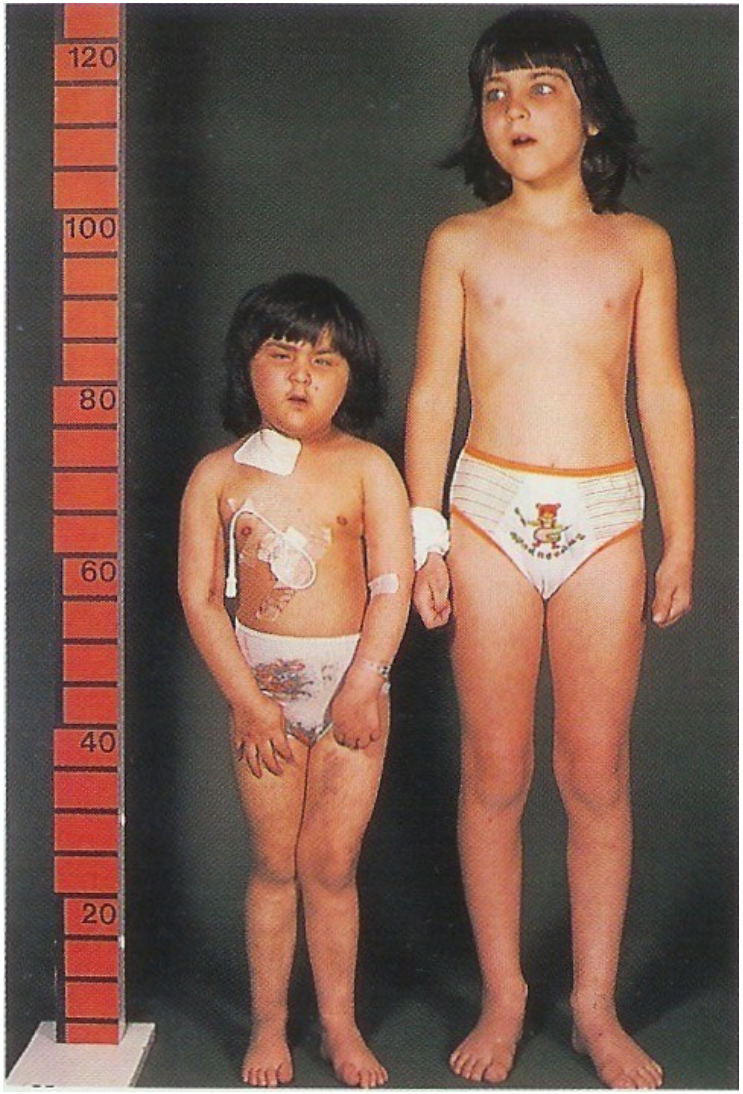
120
100
80
60
40
20

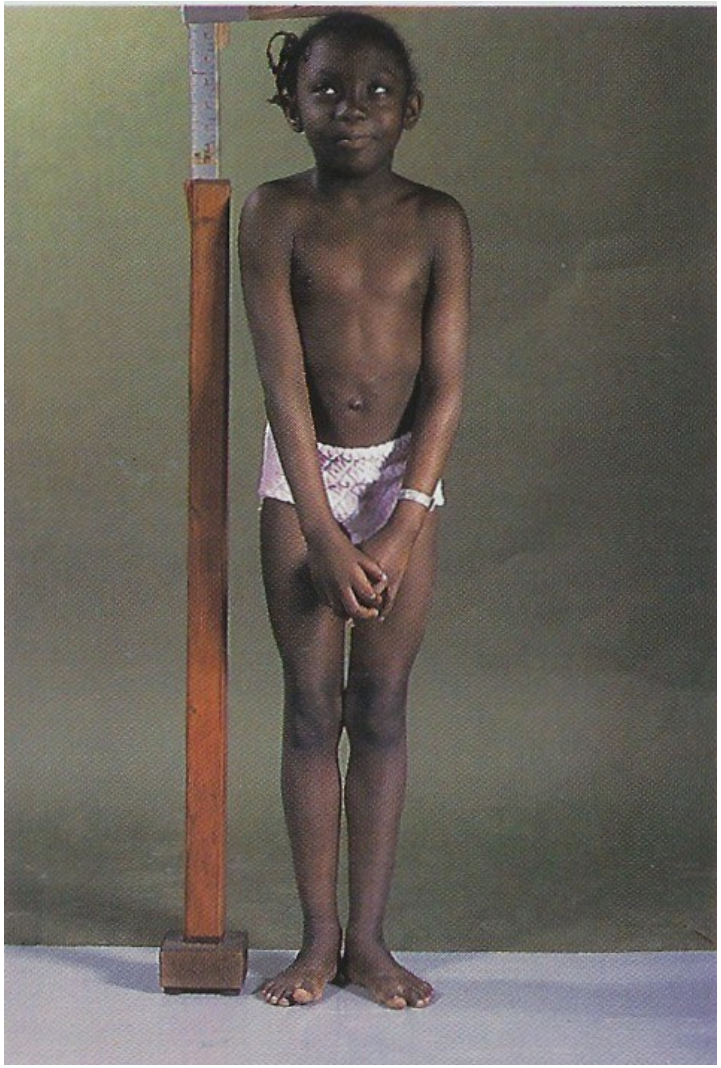

Usual age of presentation:

- 5-10 years

Complications:

- 10% of cases develop AML
- Malignancy of other organs e.g. skin